

# Gastric Volvulus Management by Laparoscopic Surgical Procedure, Prognosis: Review

<sup>1</sup>Messedah Awad Rajab Al Daya, <sup>2</sup>Manal Ahmad Ali Assiri

---

**Abstract:** Gastric volvulus (GV) is recognized to be a lethal condition, thus timely medical diagnosis and treatment is imperative. This review was aiming to discuss the laparoscopic surgical procedure in treatment of Gastric volvulus (GV), we also indented in this study to evaluate the complications following this procedure and the prognosis throughout the follow up of patients. A comprehensive detailed search was performed through the PubMed/Midline, science-direct. and Embase databases to find a related articles published up to December 2016, and relevant to our study purpose,” laparoscopic management of Gastric volvulus” we restricted our study to only English language published studies with human subjects. then we also searched the references list of each identified article to find more evidence to be included in our studies. Laparoscopic surgical approach has been shown to be reliable for treating both chronic and intense gastric volvulus, while providing the benefits of minimized morbidity provided by laparoscopy. In emergency situations, in patients with high surgical risk and in cases of primary volvulus, laparoscopic anterior gastropexy is sufficient, although research studies of long-term results are required.

**Keywords:** Gastric volvulus (GV), medical diagnosis, treatment, emergency situations, surgical risk.

---

## 1. INTRODUCTION

Gastric volvulus (GV) is recognized to be a lethal condition, thus timely medical diagnosis and treatment is imperative <sup>(1)</sup>. It is identified by irregular rotation of the stomach of more than 180 °. It was first explained in 1866 by Berti based on the autopsy of a 61-year old woman <sup>(2)</sup>. The peak age of occurrence is in the 5th decade with children less than one-year-old making up 10-- 20% of cases. No association with either sex or race has been reported <sup>(3,4)</sup>. In 30% of cases the volvulus takes place as a main event, however it is more commonly secondary to another cause <sup>(3,5)</sup>. The main repercussion of the condition is foregut blockage that might be severe, recurrent, periodic or chronic <sup>(4,6,7)</sup>. Moreover, there is a risk of strangulation which may result in necrosis, perforation and hypovolaemic shock. The mortality rates for severe volvulus range from 30 to 50% highlighting the value of early medical diagnosis and treatment <sup>(3,5,6,8,9)</sup>.

Its most regular presentation is chronic, which is associated with type II-- III hiatal hernias <sup>(10)</sup>. Medically, it might run its course either without signs or with a series of non-specific signs, such as the feeling of stomach fullness, intermittent epigastric pain that sometimes radiates towards the left hemithorax, persistent anemia, dysphagia or meteorism <sup>(4,10)</sup>.

Treatment of gastric volvulus has actually changed over recent decades. Upon medical diagnosis of the condition the patient ought to be kept susceptible and a nasogastric tube placed to facilitate decompression <sup>(4,6)</sup>. Immediate surgical assessment must then be acquired, particularly when it comes to an acute volvulus where the risk of vascular compromise and death are high <sup>(11)</sup>. For the majority of cases personnel intervention will be planned however effective results have been reported with a conservative technique too <sup>(5,6)</sup>.

Despite several operations being available, it is open surgical reduction with or without gastropexy that is most often carried out. Nevertheless, due to the dangers related to such significant open surgical treatment a more conservative approach to management has actually also been mentioned. This tends to be restricted to either the senior population or

those with chronic gastric volvulus. Less intrusive techniques presently utilized include laparoscopic surgery or endoscopic decrease with insertion of a percutaneous gastrostomy tube<sup>(3,4,5,8)</sup>. The principal objectives of surgical treatment consist of reduction of the volvulus, the avoidance of reoccurrence and fixing any predisposing factors such as diaphragmatic problems<sup>(7,8)</sup>.

Surgical approach of GV has actually altered recently from traditional surgical treatment to laparoscopic approach, since this represents appropriate handling with minor morbidity, particularly in elderly patients. However, in comparative studies it does not vary from open surgery<sup>(3,9)</sup>.

This review was aiming to discuss the laparoscopic surgical procedure in treatment of Gastric volvulus (GV), we also indented in this study to evaluate the complications following this procedure and the prognosis throughout the follow up of patients.

## 2. METHODOLOGY

A comprehensive detailed search was performed through the PubMed/Midline, science-direct. and Embase databases to find a related articles published up to December 2016, and relevant to our study purpose," laparoscopic management of Gastric volvulus" we restricted our study to only English language published studies with human subjects. then we also searched the references list of each identified article to find more evidence to be included in our studies. We included review, systematic reviews, randomized control studies (RCTs), and case reports.

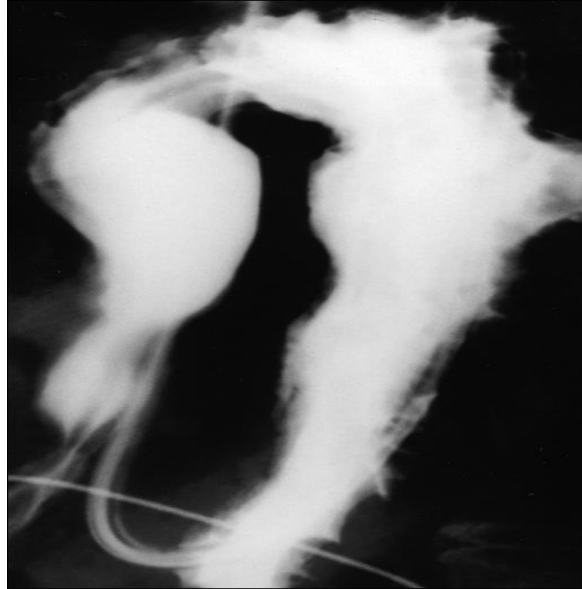
## 3. RESULTS

### o Classification of Gastric volvulus:

Anatomically, GV is categorized based upon the axis of rotation: mesentero-axial and organo-axial (**Figure1**)<sup>(9)</sup>. When the stomach turns on its small axis from the lower curvature to the major one and is regularly periodic, the first type is produced<sup>(9)</sup>. The second type is the organo-axial volvulus; this happens when the stomach rotates on its long axis, the stomach then turns anteriorly and par excellence, typically in conjunction with diaphragmatic flaws. Strangulation and vascular compromise might happen and typically this is an acute event<sup>(12,13)</sup>.

Gastric volvulus is traditionally thought of as an intra-abdominal condition. There are reports though of an intra-thoracic version, which although unusual, is thought about a surgical emergency situation due to the risk of ischaemic necrosis, perforation and severe cardiorespiratory compromise<sup>(9)</sup>. It is therefore vital that medical diagnosis and treatment are not delayed. In addition to its site, gastric volvulus may likewise be categorized according to its cause, axis of rotation and whether it provides acutely or chronically.

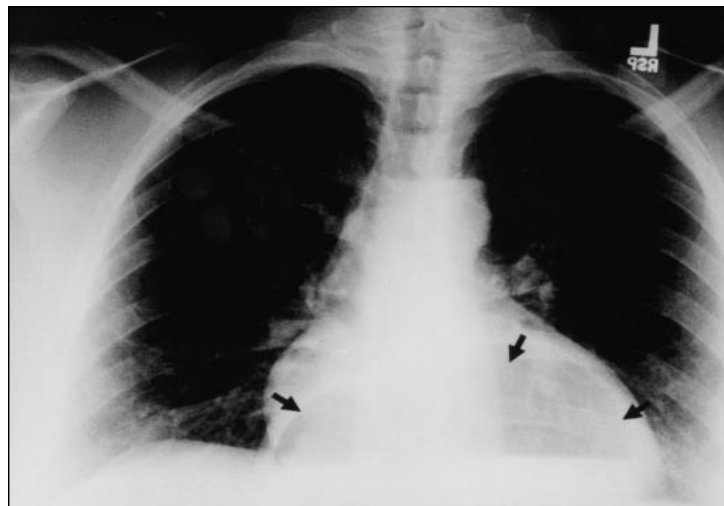
Based upon aetiology, both main and secondary forms of gastric volvulus have actually been identified. The main (idiopathic) subtype happens as a result of neoplasia, adhesions or an irregularity in the accessory of the stomach. Relating to the latter, the stomach is generally fixed to the abdominal wall by four ligaments: the gastrocolic, gastrohepatic, gastrophrenic, and gastrosplenic. Together with the gastroesophageal and the pylorus junction, these ligaments provide anchorage and therefore avoid malrotation. Failure of these encouraging systems as a result of agenesis, elongation, or interruption of the gastric ligaments might incline to primary gastric volvulus. Alternatively, a secondary gastric volvulus might occur because of disorders of gastric anatomy or gastric function or problems of adjacent organs such as the diaphragm or spleen. In grownups, the most typical association is with a para-esophageal hernia however traumatic problems, diaphragmatic eventration and phrenic nerve paralysis have also been reported<sup>(4,6,7,11)</sup>. The 3 staying classifications of gastric volvulus that exist are specified according to their axes of rotation. Organo-axial volvulus is the most common. Happening in 60% of cases, this subtype is related to para-esophageal hernias and diaphragmatic eventration. It is characterised by rotation around an axis adjoining the gastroesophageal junction and the pylorus and therefore causes the greater curvature of the stomach to rest superior to the lower curvature, leading to an 'inverted' stomach. The differentiating function of this specific variant is that it lies in the horizontal plane when viewed on plain radiography, a fact that may help with medical diagnosis<sup>(4,6,11)</sup>.



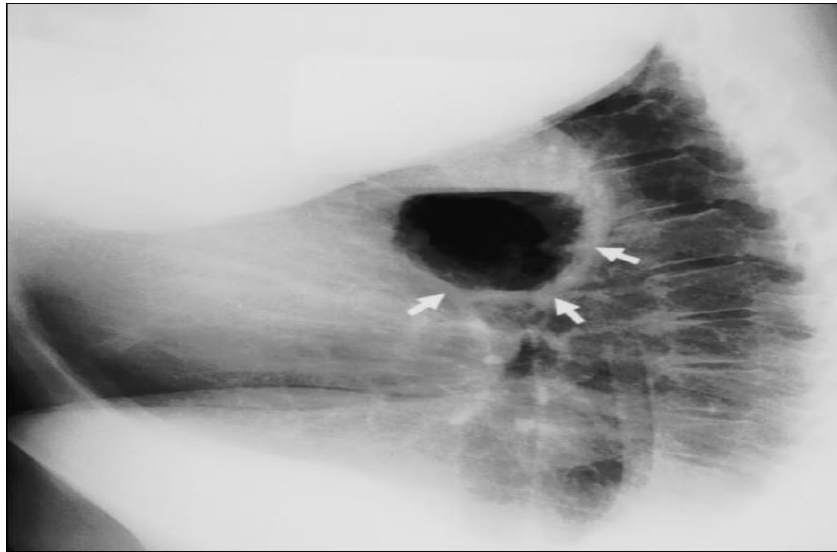
**Figure1:** The stomach as it appears after upper GI contrast study showing an organoaxial volvulus (“upside-down stomach”). Note position of the nasogastric tube as it courses through the gastroesophageal junction below the diaphragm and turns 180° back into the thoracic cavity. <sup>(9)</sup>

○ **Clinical symptoms:**

The clinical presentation of patients with gastric volvulus relies on the speed of beginning, the type of volvulus and the degree of blockage. Those with the acute form present with pain in the upper abdomen or lower chest associated with extreme retching <sup>(4,7,11)</sup>. Adults with intense gastric volvulus normally present with serious epigastric pain and distention, ineffective vomiting and trouble with nasogastric tube insertion. This triad of symptoms is known as Borchart's triad <sup>(14)</sup>. Carter et al <sup>(15)</sup> included additional scientific features that consist of the following: 1) very little stomach findings when volvulus is intrathoracic; 2) gas-filled viscus in the lower chest or upper abdominal area as seen on chest radiograph (**Figure 2 & 3**) <sup>(9)</sup> obstruction seen on upper GI contrast research studies at the site of the volvulus <sup>(3)</sup>. Hematemesis may likewise be seen and is thought to occur due to mucosal sloughing as a result of ischemia or a mucosal tear due to retching <sup>(6,11)</sup>. In contrast, patients who have a chronic gastric volvulus might provide with nonspecific symptoms which may go undetected. These include moderate upper stomach pain, dysphagia, bloating, and pyrosis <sup>(9)</sup>. A chronic gastric volvulus can present with irregular chest pain, anemia (probably due to Cameron disintegrations), weight loss, dyspnea and reflux. When the stomach is in the regular anatomic position, it is anchored by the gastrocolic, gastrosplenic, gastrohepatic and gastroduodenal ligaments. The gastrocolic and/or gastrosplenic ligaments can end up being extended, attenuated, and redundant and, following specific personnel procedures, transected. When this occurs, the stomach can then rotate more than 180 ° and form a volvulus <sup>(1)</sup>.



**Figure2:** Chest radiograph showing air-filled viscus in an intrathoracic position behind the cardiac silhouette (black arrows). <sup>(9)</sup>



**Figure3: Lateral chest radiograph showing the same air-filled radiograph showing the same air-filled viscus in an intrathoracic position behind the heart (white arrows).<sup>(9)</sup>**

○ **Diagnostic procedure of GV:**

Gastric volvulus is an uncommon condition that is hardly ever considered in the very first instance when a patient presents with stomach or chest pain related to queasiness and throwing up. Diagnosis is for that reason tough and is conventionally achieved radiologically in patients with suitable clinical findings. Chest radiographs show a retrocardiac, air-filled mass (**Figure 2**)<sup>(9)</sup> whereas stomach films show an increased soft-tissue density in the upper abdominal area consistent with a distended fluid-filled stomach. However, these functions might be absent in cases of periodic blockage and for that reason more imaging is frequently needed to validate medical diagnosis<sup>(9)</sup>. This is usually attained utilizing either upper intestinal barium studies or computer system tomography<sup>(3,4,5,9)</sup>. In accordance with Teague et al,<sup>(5)</sup> it is barium studies that are most dependable being diagnostic in 14 of 25 observed cases.

○ **Laparoscopic Treatment of GV and its complications:**

The treatment of gastric volvulus is surgical and generally consists of the surgical correction of associated factors. The laparoscopic approach has actually been able to decrease surgical hostility of the procedure in these outcomes and patients have been published of its use not just in the management of chronic gastric volvulus associated with hiatal hernia, however also in intense circumstances<sup>(9,16,17,18)</sup>. Surgical correction is not risk-free however reliable, even with laparoscopy: vagus injury, pneumothorax, hemorrhage recurrence of volvulus can happen<sup>(18,19)</sup>. Experience from our 4 cases of gastric volvulus has actually shown that a laparoscopic technique with excision of the hernia sac, reapproximation of the diaphragmatic crura, an anti-reflux procedure and laparoscopic gastrostomy tube placement, when suggested, has actually been endured by all of our patients<sup>(9,17)</sup>. The laparoscopic gastrostomy tube secures the stomach intra-abdominally and assists avoid migration of the stomach to an intrathoracic position. Complete excision of the hernia sac can assist remove one cause for recurrence, as described by Williamson and Ellis<sup>(20)</sup>. As the advancement of laparoscopic methods continues, there will be less require for a combined endoscopic reduction and laparoscopic gastropexy, which remains a feasible choice in the high-risk patient. This combined method overlooks among the basic tenets in the treatment of gastric volvulus by cannot repair the diaphragmatic flaw, leaving the potential for recurrent hernia along with recurrent volvulus. But most severe gastric volvuli generally present in patients with bad basic conditions who need emergency surgical intervention and in the elderly with high surgical risk. These situations make it difficult to consider a standard surgical repair, as this would involve long surgical times and high morbidity, and we for that reason select laparoscopic anterior gastropexy, without resecting the sac or correcting the hiatal defect. Fixation was finished with basic sutures, although other authors have actually used overall transparietal stitches<sup>(21,22)</sup> or perhaps the placement of a percutaneous endoscopic gastrostomy (PEG) connected with the gastropexy for a time or even definitively<sup>(23,24)</sup>. We believe that PEG is an aggressive and unnecessary procedure that does not eliminate the possibility of volvulus, since volvulus around the PEG has actually been reported, as it can function as a torsion axis<sup>(25,26)</sup>. Laparoscopic anterior gastropexy as a single procedure seems to be a safe and reliable treatment that resolves the emergency situation<sup>(27,28)</sup>. In 2013, there remains no agreement among foregut cosmetic surgeons regarding the ideal surgical technique to giant hiatal

hernias. The methods include trans-abdominal vs trans-thoracic procedures, open vs laparoscopic procedures, hiatal closure with main stitch vs using meshes, fundoplication, gastroplasty and total sac excision. As literature had substantial experience in more than 1000 anti-reflux operations, a laparoscopic technique was the treatment of choice in our series. Some cosmetic surgeons promote the transthoracic technique specifically in emergency situation cases<sup>(29)</sup>. The improved ability to different adhesions in between the hernia sac and pleura is the main benefit of transthoracic repair. Over the last few years, effective thoracoscopic repair work of intrathoracic stomach has actually started to appear in the literature<sup>(30)</sup>. The cosmetic surgeon's experience seems to be the most essential consideration in choosing the procedure.

The dispute over total excision of the hernia sac is the least controversial issue. Lots of cosmetic surgeons believe overall excision of the sac removes the stress on the GEJ and lessens the risk of reoccurrence. Edye et al<sup>(31)</sup> addressed this problem and reported 20% early period reoccurrence in patients without sac excision. Although the overall excision of the sac reduces the reoccurrence rates, some cosmetic surgeons choose to leave the distal part of the sac as a foolproof measure to counter troubles in dissecting nearby pleura and vagal nerves.

#### 4. CONCLUSION

Laparoscopic surgical approach has been shown to be reliable for treating both chronic and intense gastric volvulus, while providing the benefits of minimized morbidity provided by laparoscopy. In emergency situations, in patients with high surgical risk and in cases of primary volvulus, laparoscopic anterior gastropexy is sufficient, although research studies of long-term results are required. Complete excision of the hernia sac, closure of the hiatal problem, and anterior gastropexy. The laparoscopic gastrostomy tube secures the stomach intra-abdominally and assists avoid migration of the stomach to an intrathoracic position.

#### REFERENCES

- [1] N.M. Flanagan, J. McAloon. Gastric volvulus complicating cerebral palsy with kyphoscoliosis. *Ulster Med J*, 72 (2003), pp. 118–120.
- [2] Berti. Singolare attortigliamento dell'esofago col duodeno sequito da rapida morte. *Gazz Med Ital*, 9 (1866), pp. 139–141
- [3] Chau, S. Dufel. Gastric volvulus. *Emerg Med J*, 24 (2007), pp. 446–447
- [4] D.P. McElreath, K.W. Olden, F. Aduli. Hiccups: a subtle sign in the clinical diagnosis of gastric volvulus and a review of the literature. *Dig Dis Sci*, 53 (2008), pp. 3033–3036
- [5] W.J. Teague, R. Ackroyd, D.I. Watson, P.G. Devitt. Changing patterns in the management of gastric volvulus over 14 years. *Br J Surg*, 87 (2000), pp. 358–361
- [6] R.K. Cribbs, K.W. Gow, M.L. Wulkan. Gastric volvulus in infants and children. *Pediatrics*, 122 (2008), pp. e752–e762
- [7] D. Godshall, U. Mossallam, R. Rosenbaum. Gastric volvulus: case report and review of the literature. *J Emerg Med*, 17 (1999), pp. 837–840
- [8] A.H. Al-Salem. Acute and chronic gastric volvulus in infants and children: who should be treated surgically?. *Pediatr Surg Int*, 23 (2007), pp. 1095–1099
- [9] Channer LT, Squires GT, Price PD. Laparoscopic Repair of Gastric Volvulus. *JSLS: Journal of the Society of Laparoendoscopic Surgeons*. 2000;4(3):225-230.
- [10] H. Kuwano, M. Hashizume, M. Ohta, K. Sumiyoshi, K. Sugimachi, Y. Haraguchi. Laparoscopic repair of a paraesophageal hiatal hernia with gastric volvulus. *Hepatogastroenterology*, 45 (1998), pp. 303-306.
- [11] G. Shivanand, S. Seema, D.N. Srivastava, G.K. Pande, P. Sahni, R. Prasad, *et al*. Gastric volvulus: acute and chronic presentation. *Clin Imaging*, 27 (2003), pp. 265–268.
- [12] arford W, Jeyarajah R. Abdominal hernias and their complications, including gastric volvulus. En: Sleisenger MH, Fordtran JS eds. *Gastrointestinal and liver disease 7th edn*. Philadelphia: WB Saunders 2002; 375-383.
- [13] Godshall D, Mossallem U, Rosenbaum R. Gastric volvulus: case report and review of the literature. *J Emerg Med* 1999;17:837-840.

- [14] Borchardt M. Zur pathologie and therapy des magnevolvulus. Arch Klin Chir. 1904;74:243–248
- [15] Carter R, Rewer LA, Hinshaw DB. Acute gastric volvulus. Am J Surg. 1980;140:99–106
- [16] N. Kathkouda, E. Mayor, K. Achanta, M.H. Friedlander, S.W. Grant, R. Essani. Laparoscopic repair of chronic intrathoracic gastric volvulus. Surgery, 128 (2000), pp. 784-790
- [17] J.D. Luketitch, S. Raja, H.C. Fernando, W. Campbell, N.A. Christie, P.O. Buenaventura. Laparoscopic repair of giant paraesophageal hernia: 100 consecutive cases. Ann Surg, 232 (2000), pp. 608-618
- [18] K. Sato, C.J. Filipi, Y. Shiino, S.K. Mittal, K. Zacher, G.C. Gardner. An unusual case of gastric volvulus after laparoscopic paraesophageal hernia repair. Surg Endosc, 15 (2001), pp. 757.
- [19] T.L. Trus, T. Bax, W.S. Richardson, G.D. Branum, S.J. Mauren, L.L. Swanson. Complications of laparoscopic paraesophageal hernia repair. J Gastrointest Surg, 1 (1997), pp. 221-228
- [20] Williamson WA, Ellis FH. Paraesophageal hiatal hernia: Is an antireflux procedure necessary? Ann Thorac Surg. 1993;56:447–452
- [21] D. Bhandarkar, R. Shah, P. Dhawan. Laparoscopic for chronic intermittent gastric volvulus. Indian J Gastroenterol, 20 (2001), pp. 111-112
- [22] J. Schleaf, S. Von Bismarck. An easy method for laparoscopic assisted percutaneous anterior gastropexy. Surg Endosc, 14 (2000), pp. 964-965
- [23] J.S. Baudet, J.R. Armengol-Miro, C. Medina, A.M. Accarino, J. Vilaseca, J.R. Malagelada. Percutaneous endoscopic gastrostomy as a treatment for chronic gastric volvulus. Endoscopy, 29 (1997), pp. 147-148
- [24] Beqiri, W.E. Vandekolk, D. Scheeres. Combined endoscopic and laparoscopic management of chronic gastric volvulus. Gastrointest Endosc, 46 (1997), pp. 450-452
- [25] Alawadhi, S. Chou, P. Soucy. Gastric volvulus—a late complication of gastrostomy. Can J Surg, 34 (1991), pp. 485-486
- [26] U. Morelli, M. Bravetti, P. Ronca, R. Ciocchi, A. De Sol, A. Spizzirri. Laparoscopic anterior gastropexy for chronic recurrent gastric volvulus: a case report. J Med Case Rep, 2 (2008), pp. 244
- [27] Naim, R. Smith, P. Gorecki. Emergent laparoscopic reduction of acute gastric volvulus with anterior gastropexy. Surg Laparosc Endosc Percutan Tech, 13 (2003), pp. 389-391
- [28] M. Hashemi, J.H. Peters, T.R. DeMeester, J.E. Huprich, M. Quel, J.A. Hagen. Laparoscopic repair of large type III hiatal hernia: objective follow-up reveals high recurrence rate. J Am Coll Surg, 190 (2000), pp. 553-560
- [29] Kim HH, Park SJ, Park MI, Moon W. Acute Intrathoracic Gastric Volvulus due to Diaphragmatic Hernia: A Rare Emergency Easily Overlooked. Case Rep Gastroenterol. 2011;5:272–277.
- [30] Liem NT, Nhat LQ, Tuan TM, Dung le A, Ung NQ, Dien TM. Thoracoscopic repair for congenital diaphragmatic hernia: experience with 139 cases. J Laparoendosc Adv Surg Tech A. 2011;21:267–270. [
- [31] Edye M, Salky B, Posner A, Fierer A. Sac excision is essential to adequate laparoscopic repair of paraesophageal hernia. Surg Endosc. 1998;12:1259–1263.